

Ricardo Gómez Betancourt • Forma colposcópica o Biopsia cervical

Fecha: _____

Infectada por VPH: _____

Nombre: _____

HISTORIA: Edad: _____

Fumadora: Si No

Reporte citológico/biopsia previa: _____

Colposcopia o Biopsia:

Satisfactoria No Satisfactoria

Evaluación general: _____

Pap repetida: si no

LANDMARKS and ATYPICAL FINDINGS:

TZ = transformation zone

SC = new squamocolumnar junction

NC = Nabothian cyst

ME = immature squamous metaplasia

PO = polyp

AV = atypical vessels

C = condyloma

L = leep

AW = acetowhite epithelium

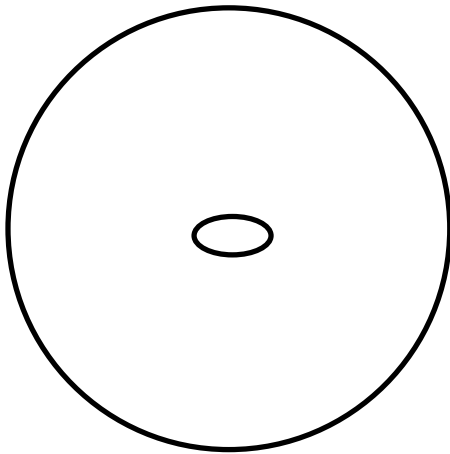
P = punctation

MO = mosaicism

LS = decreased Lugol's uptake

X = biopsy sites

CA = invasive carcinoma



Se realiza LEEP: si no

Reid's Colposcopic Index:

Margin _____

Color _____

Vessels _____

Iodine _____

Total _____

IMPRESION: _____

RESULTADOS

Biopsia: _____

PAP: _____

Controles (fechas y resultados): _____

Curada _____